

Melkersson-Rosenthal syndrome: Review of the literature and case report of a 10-year misdiagnosis

Ben Balevi*

Abstract *Melkersson-Rosenthal syndrome is classically described as a triad of orofacial swelling, facial palsy, and fissured tongue. More often this syndrome presents in its oligosymptomatic forms. Melkersson-Rosenthal syndrome may not be as rare as suspected but rather a syndrome that often goes undiagnosed. Presented is the case of a mentally challenged man who was eventually diagnosed with Melkersson-Rosenthal syndrome only after being misdiagnosed and incorrectly treated for an odontogenic infection for more than a decade. (Quintessence Int 1997;28:265-269.)*

Introduction

Melkersson reported a case of idiopathic facial swelling associated with facial palsy in 1928. Three years later, Rosenthal added fissured tongue to complete the description of the syndromic triad that was later called *Melkersson-Rosenthal syndrome (MRS)*.¹

Melkersson-Rosenthal syndrome usually presents in a monosymptomatic or oligosymptomatic form. Hornstein² reported the complete form in 8% of 73 patients with MRS, while Worsaae et al³ found the complete form to constitute 18% of the 33 cases they studied. Green and Rogers⁴ reported on 36 cases of recurrent orofacial edema observed at the Mayo Clinic between 1970 and 1987. They found that the true triad of MRS was found in as high as 25% of the patients. The oligosymptomatic forms, facial palsy with orofacial swelling and orofacial swelling with fissured tongue, were found in 22% and 25% of the patients, respectively. Orofacial swelling occurred alone in 28% of those affected.

Melkersson-Rosenthal syndrome is considered to be a rare syndrome. Hornstein² estimated the incidence to be 0.08%. Others have reported the incidence to be less than 0.05%.⁵ An accurate incidence of MRS is difficult to determine because it more often presents in its oligosymptomatic form.

Therefore, MRS may not be rare because it may often go undiagnosed. Presented is the case of a mentally challenged man who was eventually diagnosed with MRS only after being misdiagnosed and incorrectly treated for an odontogenic infection for more than a decade.

Case report

A 39-year-old white man, a long-term resident of the Huronia Regional Centre, was referred to the dental clinic for assessment of facial swelling. A similar episode of facial swelling had occurred 6 months earlier.

The Huronia Regional Centre is one of the largest institutions for the mentally challenged in Ontario. It presently cares for more than 650 low- to moderately low-functioning residents. Residents are examined biannually in the institution's dental clinic. The dental clinic acts as a teaching rotation for dental residents from the University of Toronto. These dental residents are supervised by two part-time dentists, working alternate days. It is not unusual for a mentally challenged resident to have been examined by many different dentists through the years.

This nonverbal trisomy-21 man was taking levothyroxine, 0.5 mg per day, for the management of hypothyroidism. He did not have a history of self-abusing behavior, and he kept good personal hygiene. Oral examination revealed a nonedematous moderate swelling of the face, localized around the upper right

* Private Practice, Madoc, Ontario, Canada.

Reprint requests: Dr Ben Balevi, PO Box 267, 39 St Lawrence Street East, Madoc, Ontario K0K 2K0, Canada.

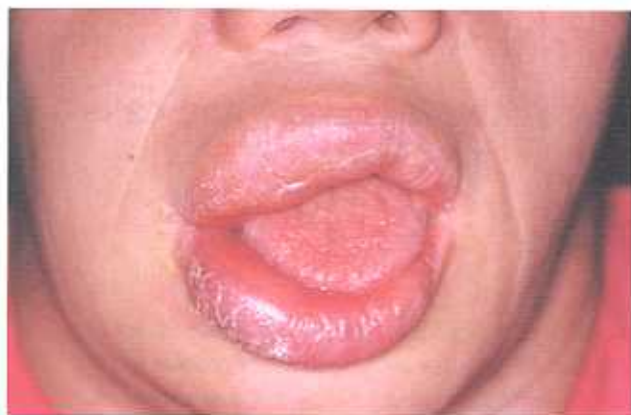

Fig 1 Labial swelling on the right side.

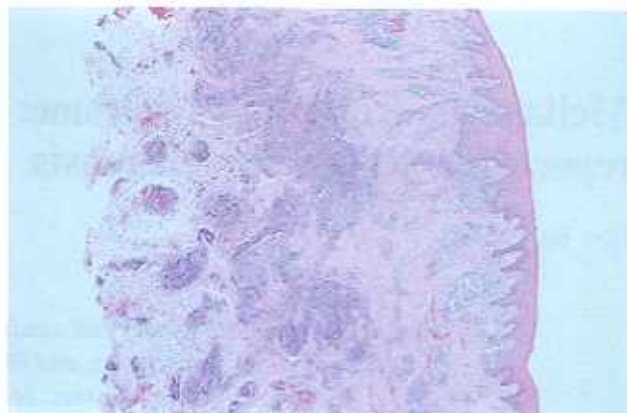


Fig 2 Histopathology of the affected lip. (Original magnification $\times 500$.)

lip area (Fig 1). The swelling had normal temperature, was not painful, and was nonpitting and rubbery in consistency.

The tongue had deep grooves and fissures. This can be discerned somewhat in Fig 1. All the maxillary right molars and premolars (teeth 1 [18], 2 [17], 3 [16], 4 [15], and 5 [14]) were missing, as were the mandibular right molars (32 [48], 31 [47], and 30 [46]). All other teeth on that side appeared clinically sound, without signs of active coronal caries. Also, he did not seem to react as if he was in pain to dental percussion and palpation of the adjacent oral structures. He had moderate periodontitis but no signs of acute periodontal or gingival inflammation. Periapical radiographic findings of the maxillary and mandibular teeth on the right were unremarkable.

An initial diagnosis of angioedema was made. Diphenhydramine hydrochloride, 100 mg, was administered intramuscularly followed by a course of diphenhydramine hydrochloride, 50 mg orally, four times a day. After 24 hours no noticeable reduction in facial swelling was evident. Therefore, reevaluation of the diagnosis was necessary.

Review of the resident's dental record revealed 12 previous episodes of facial swelling on his right side dating back 10 years; eight of the episodes were within the last 5 years. During the past decade, he had been examined by 14 different dentists. Initially, he was diagnosed with dental abscesses. Teeth 14 and 15 were endodontically treated before they were finally extracted 5 years later. Within this initial 5-year period, tooth 47 was extracted following an episode of the recurrent facial swelling. Within the latter 5 years, numerous regimens of antibiotic therapy were prescribed but without a 1-week follow-up.

As a result of this history, recurrent cheilitis granulomatosa consistent with MRS was added to the differential diagnosis. A biopsy specimen of the affected lip area was sent for histopathologic examination, confirming the final diagnosis of MRS. The mucosa consisted of parakeratinized, hyperplastic, stratified squamous epithelium overlying collagenous connective tissue. Within the connective tissue there were discrete aggregations of lymphocytes, generally with a perivascular distribution; however, some had central foci of histiocytes consistent with granulomatous lesions. The histologic findings were consistent with cheilitis granulomatosa (Fig 2).

Treatment consisted of application of lip gloss to prevent cracking of the exposed mucosa. No further treatment was deemed necessary except continuation of his regular biannual preventive recall appointments.

Discussion

Melkersson-Rosenthal syndrome is classically described as a triad of orofacial swelling, facial palsy, and fissured tongue. More often this syndrome presents in its oligosymptomatic forms. Melkersson-Rosenthal syndrome may often go undiagnosed, as in the present case.

Although MRS is reported as commonly found during the second to fourth decades of life, there are many published reports of MRS in children and preadolescents. Roseman et al⁶ described a case of MRS in a 7-year-old girl. Cohen et al⁷ described four cases of MRS in children younger than the age of 11 years, and Yuzuk et al⁸ described the case of a 13-year-old girl who presented with the oligosymptom-

atic form of labial edema coupled with fissured tongue. Melkersson-Rosenthal syndrome does not appear to have an obvious predilection for either sex, although some claim that it is slightly more common in females.^{5,7,9}

Melkersson-Rosenthal syndrome was mistakenly believed to be manifested "exclusively in white persons."^{7,10} This is because most cases reported in the literature were from countries with a predominantly white population.^{2,4} Isolated cases have been reported in South Africa,¹¹ the Middle East,^{7,12} India,¹³ and Japan.¹⁴ Thus, it appears that MRS has no racial predilection.

Initially, a patient with MRS usually complains of nonpainful facial swelling that has persisted for a long time. Further investigation may reveal a history of previous episodes of swelling associated with facial paralysis or fissured tongue that the patient has never connected.

The most common symptom of MRS is recurring orofacial swelling in which the upper lip is more often affected. The monosymptomatic presentation of MRS involving only the lip is referred to as *cheilitis granulomatosa* or *Miescher's cheilitis*.¹⁵ Other areas affected by orofacial swelling in MRS are, in order of frequency, the cheek, nose, eyelid, alveolar process, and chin.^{16,17}

Zimmer et al¹⁶ reported orofacial manifestations in 42 patients with MRS who were examined at their clinic; they also reviewed 220 cases reported in the literature between 1965 and 1990. They found that 82% of patients presented with labial swelling, 40% had swelling in other parts of the face, not including the lip, 24% had Bell's palsy, and 59% had fissured tongue. Other areas of intraoral swelling were, in order of frequency, the gingiva (11%), buccal mucosa (16%), palate (8%), and tongue (7%). Jayamaha¹⁸ recently reported a case of a woman with a long history of MRS, who, at the age of 21 years, developed pharyngeal and laryngeal swelling that was life threatening.

The etiology and pathogenesis of lesions associated with MRS are unknown. Hornstien² suggested that abnormal regulation of the autonomic nervous system leads to excessive permeability of the facial cutaneous vessels. From this abnormal circulation, nonspecific antigens then stimulate the perivascular cells to form granulomas. Obstruction of perivascular vessels by granuloma has been proposed as a causative factor in the swelling.²

Zimmer et al¹⁶ and Green and Rogers,⁴ in reviewing numerous cases of MRS, found a limited genetic or familial component. This low frequency of MRS in

relatives is supported by Meisel-Stosiek et al,¹⁹ who looked at the genetic and familial basis of the disease. However, they concluded that MRS has a multifactorial origin that they believe includes a genetic predisposition. Nevertheless, Smeets et al²⁰ have suggested the possible location of the MRS gene.

Because of the recurrent nature of the lesions, a viral component, as is the case with herpes simplex, is believed by some to be involved. Thus far, there is no evidence in support of this hypothesis.^{18,21,22}

Allergies and autoimmunity are also believed to be involved. Yet many describe the facial swelling to be nonresponsive to antihistamines, thus not supporting such an etiology. Nevertheless, Pachor et al²³ described a possible case of MRS involving labial swelling and fissured tongue. Swelling of the lip was believed to be triggered by food additives. Once the food additive was removed, the lesions receded. On the other hand, Morales et al²⁴ were unable to establish an etiologic role of food additives in six patients already diagnosed with MRS.

The swelling of the face and lip is described as nontender, nonpitting, and firm, but not of hard consistency. The orofacial swelling is usually sudden and, in most cases, precedes facial paralysis by weeks, months, and even years.^{4,5,16} Each recurrent episode is believed to be more pronounced and of longer duration, and swelling may eventually become permanent.^{4,5,16,25}

The facial paralysis associated with MRS is frequently indistinguishable from Bell's palsy. The site affected by paralysis usually corresponds to the site of swelling. As in the case with facial swelling, the paralysis is generally self-limiting with complete recovery. Similarly, each recurring episode is more profound and lasts longer.^{5,11,12} Other neurologic presentations associated with MRS are altered taste, migraine headaches, and trigeminal neuralgia.^{4,5,11,16,17}

Fissured tongue (eg, lingual plicata) is usually found at birth and therefore considered an incidental finding of MRS. Nevertheless, fissured tongue is ten times more likely to be found among individuals diagnosed with MRS than in the general population.^{5,16,17} Miyashita et al²⁶ described MRS in a 56-year-old woman, who was afflicted with cheilitis granulomatosa caused by lingual candidiasis of a fissured tongue. The lip swelling resolved soon after proper oral hygiene was established and complemented with a regimen of systemic antifungal agents.

The edematous lesion, on histopathologic investigation, is a noncaseating epithelial cell granuloma with perivascular mononucleated lymphocytic infiltrate.

Fibrosis of the granulomas is typical in long-term and recurrent lesions.^{2,10,16,22}

Once odontogenic infection is ruled out, the differential diagnosis should also include Crohn's disease, sarcoidosis, Ascher's syndrome, and allergic angioedema.^{2,4,13,17,22,27,28}

A final diagnosis of MRS is made from the clinical history and histopathologic assessment of the edematous tissue, which usually includes the lip. When biopsy of the edematous tissue is difficult or not warranted, then a history of recurrent idiopathic facial swelling associated with at least one of the following two entities, idiopathic facial paralysis (ie, Bell's palsy) or fissured tongue, is sufficient to make a positive diagnosis of MRS.

Treatment of MRS is aimed at the facial swelling and the paralysis. Because the etiology and pathogenesis of MRS are not well understood, treatment continues to be empirical and, in most cases, unsuccessful. Fortunately, both the swelling and the paralysis are self-limiting and usually go into remission on their own. Nevertheless, recurrent episodes of facial swelling and facial paralysis become longer lasting and may eventually become permanent. This may result in loss of function and be of esthetic concern to some.

Facial paralysis is usually managed as typical Bell's palsy. Treatment with oral prednisone or nerve decompression has been shown to be effective.^{2,4,5}

Radiotherapy, antihistamines, and salazosulfapyridine have all been shown to be unpredictable in managing the granulomatous lesions of MRS.^{4,13} The same holds true with danazol, which is regularly used for the management of fibrocystic breast disease.^{12,22} One case report has shown methotrexate, an anti-neoplastic drug, to be beneficial.²⁹ Mahler et al³⁰ reported successful management of granulomatous glossitis, an unusual manifestation of MRS, with clofazimine. Although antibiotics are generally considered to be ineffective, two groups have reported successful results with minocycline³¹ and metronidazole.¹⁴ Also, interlesional injections with triamcinolone hexacetonide suspension have been shown to provide temporary benefit.¹⁵

Plastic surgery may be considered in the case of permanent fibrotic lesions.⁹ Ellitsgaard et al²⁵ followed 13 patients who had undergone labial surgery. They found that 16 years postsurgery, results were considered successful in 12 patients.

The present report describes the case of a mentally challenged man diagnosed with MRS. The significance of this case is not so much its clinical presentation as its clinical history, particularly, the suspicion that this

man was misdiagnosed as having an orofacial infection and incorrectly managed for almost a decade.

Two factors played a role in the misdiagnosis in this case. First, the patient was nonverbal, making it nearly impossible for the attending dentist to attain a thorough clinical history of the presenting condition. Second, the high turnover rate of attending dentists in a dental teaching clinic made it less likely for any one dentist to recognize the recurrent nature of the condition.

Nevertheless, thorough documentation by the many rotating dentists eventually allowed MRS to be included in the differential diagnosis. This case highlights the importance of good history taking, regular follow-up, and thorough documentation for proper patient management.

Acknowledgments

The author wishes to thank Dr Marisa Pavone for preparing the histologic photograph and Mrs Leanne Breen for helping prepare the manuscript.

References

- Pearce JMS. Melkersson-Rosenthal syndrome. *J Neurol Neurosurg Psychiatry* 1995;58:340.
- Hornstein OP. Melkersson-Rosenthal syndrome: A neuromucocutaneous disease of complex origin. *Curr Probl Dermatol* 1973;5:117-156.
- Worsaae N, Christensen KC, Schidt M, Reibel J. Melkersson-Rosenthal syndrome and cheilitis granulomatosa: A clinicopathologic study of thirty-three patients with special reference to their oral lesions. *Oral Surg Oral Med Oral Pathol* 1982;54:404-413.
- Green RM, Rogers RS. Melkersson-Rosenthal syndrome: A review of 36 patients. *J Am Acad Dermatol* 1989;21:1263-1270.
- Orlando MR, Atkins JS Jr. Melkersson-Rosenthal syndrome. *Arch Otolaryngol Head Neck Surg* 1990;116:728-729.
- Roseman B, Fryns JP, Van den Berghe C. Melkersson-Rosenthal syndrome in a 7-year-old girl. *Pediatrics* 1978;61:490-491.
- Cohen HA, Cohen Z, Ashkenasi A, Straussberg R, Frydman M, Kauschansky A, Varsano I. Melkersson-Rosenthal syndrome. *Cutis* 1994;54:327-328.
- Yuzuk S, Trau H, Levy A, Shewach-Miller M. Melkersson-Rosenthal syndrome. *Int J Dermatol* 1985;24:456-457.
- Glickman L, Gruss JS, Birt BD, Kohli-Dang N. The surgical management of Melkersson-Rosenthal syndrome. *Plast Reconstr Surg* 1992;89:815-821.
- Williams PM, Greenberg MS. Management of cheilitis granulomatosa. *Oral Surg Oral Med Oral Pathol* 1991;72:436-439.
- Graff-Radford SB. Melkersson-Rosenthal syndrome: A review of the literature and a case report. *South Afr Med J* 1981;60:71-74.
- Botatneh AB, Pillai KG, Mansour M, Al-Khail AA. An unusual case of the Melkersson-Rosenthal syndrome. *Oral Surg Oral Med Oral Pathol* 1995;80:289-292.
- Jain VK, Dixit VB, Khetarpal HM. Melkersson-Rosenthal syndrome: Two case reports. *Ann Dent* 1990;49(winter):30-31.
- Kano Y, Shiohara T, Yagita A, Nagashima M. Treatment of recalcitrant cheilitis granulomatosa with metronidazole. *J Am Acad Dermatol* 1992;27:629-630.

15. Mele FA Jr. The big lip. Diagnostic and treatment considerations. *Gen Dent* 1994;42:258-259.
16. Zimmer WM, Rogers RS, Reeve CM, Sheridan PJ. Orofacial manifestations of Melkersson-Rosenthal syndrome: A study of 42 patients and review of 220 cases from the literature. *Oral Surg Oral Med Oral Pathol* 1992;74:610-619.
17. Winnie R, DeLuxe DM. Melkersson-Rosenthal syndrome: Review of literature and case report. *Int J Oral Maxillofac Surg* 1992;21:115-117.
18. Jayamaha JEL. Respiratory obstruction in a patient with Melkersson-Rosenthal syndrome. *Anesth Analg* 1993;77:395-397.
19. Meisel-Stosiek M, Hornstein OP, Stosiek N. Family study on Melkersson-Rosenthal syndrome. *Acta Derm Venereol (Stockh)* 1990;70:221-226.
20. Smeets E, Fryns JP, Van den Berghe S. Melkersson-Rosenthal syndrome and de novo autosomal translocation. *Clin Genet* 1994;45:323-324.
21. Langevitz P, Engelberg JS, Tsur H, Cahili S. Melkersson-Rosenthal syndrome: An oligosymptomatic form. *South Med J* 1986;79:1159-1160.
22. Minor MW, Fox RW, Bukantz SC, Lockey RF. Melkersson-Rosenthal syndrome. *J Allergy Clin Immunol* 1987;80:64-67.
23. Pachor ML, Urbani G, Cortina P, Lunardi C, Nichols F, Peroli P, et al. Is Melkersson-Rosenthal syndrome related to the exposure of food additives? *Oral Surg Oral Med Oral Pathol* 1989;67:393-395.
24. Morales C, Peñarrocha M, Bagan JV, Barches E, Pelaez A. Immunological study of Melkersson-Rosenthal syndrome. Lack of response to food additive challenge. *Clin Exp Allerg* 1995;25:260-264.
25. Ellitsgaard N, Andersson AP, Worsaae N, Medgyesi S. Long-term results after surgical reduction cheiloplasty in patients with Melkersson-Rosenthal syndrome and cheilitis granulomatosa. *Ann Plast Surg* 1993;31:413-419.
26. Miyashita M, Baba S, Suzuki H. Role recurrent oral candidiasis associated with lingua plicata in Melkersson-Rosenthal syndrome. *Br J Dermatol* 1995;132:311-312.
27. Kano Y, Shiohara T, Yagita A, Nagashima M. Association between cheilitis granulomatosa and Crohn's disease. *J Am Acad Dermatol* 1993;28:801.
28. Lloyd DA, Payton KB, Guenter L, Frydman W. Melkersson-Rosenthal syndrome and Crohn's disease: One disease or two? Report of a case and discussion of the literature. *J Clin Gastroenterol* 1994;18:213-218.
29. Leicht S, Youngberg G, Modica L. Melkersson-Rosenthal syndrome: Elevation in serum angiotensin converting enzyme and results of treatment with methotrexate. *South Med J* 1989;82:74-76.
30. Mahler VB, Hornstein OP, Boateng BI, Kieseweller FF. Granulomatous glossitis as an unusual manifestation of Melkersson-Rosenthal syndrome. *Cutis* 1995;55:244-246.
31. Fornasa CV, Catalano P, Peserico A. Minocycline in granulomatous cheilitis: Experience with 6 cases. *Dermatologica* 1992;185:220. □

Moving Soon?

Please notify us promptly of any change of address to assure an uninterrupted subscription.

Complete the form below and send to:
 QI Subscription Department,
 Quintessence Publishing Co., Inc.,
 551 North Kimberly Drive,
 Carol Stream, IL 60188

Name _____

New address _____

City, State, ZIP _____


Moving from: _____

(Old address) _____

(City, State, ZIP) _____

Note: To expedite delivery, send the change of address as soon as you know it, and allow 6 weeks for processing.

MIRRORS FOR DENTAL PHOTOGRAPHY



- hardened glass mirror, surface optically ground and polished, edges rounded
 - special mirror shape
- hard, color neutral Rhodium mirror, coated under high vacuum
- angular handle ● special packing

Dental mirrors manufactured by FILTRÖP after long and intensive testing at the Dental Institute of the University of Basel, under the supervision of Prof. Dr. K. H. and Dr. E. M. Patetschak.

FILTRÖP AG

Distribution by:
 FILTRÖP AG, Schlössweg 24
 FL-9496 Balzers / Liechtenstein

Phone no. 0041 75 / 388 11 50
 Fax no. 0041 75 / 388 11 35